Pain Physician 2013; 16:155-164 • ISSN 1533-3159

Randomized Trial

Distribution Range of Cervical Interlaminar Epidural Injections: A Comparative Study with 2.5 mL, 5 mL, and 10 mL of Contrast

Sang Eun Lee, MD[1], Han Bum Joe, MD[2], Jae Hong Park, MD[3], In Kyong Yi, MD[3], Yi Hwa Choi, MD[3], Kyung Ream Han, MD, PhD[3], and Chan Kim, MD, PhD[3]

From: [1]Haeundae Paik Hospital, Inje University, Department of Anesthesiology and Pain Medicine, Busan, Korea; [2]Ajou University School of Medicine, Department of Anesthesiology and Pain Medicine, Suwon, Korea; [3]Kichan Pain Clinic, Seoul, Korea

Address Correspondence:
Kyung Ream Han, MD, PhD
Kichan Pain Clinic
Sinseong Misocity 1600-4
Seochogo
Seochodong
Seoul, Korea
E-mail: painhankr@naver.com

Disclaimer: There was no external funding in the preparation of this manuscript.
Conflict of interest: None.

Manuscript received: 08-18-2012
Revised manuscript received: 12-12-2012
Accepted for publication: 01-02-2013

Free full manuscript: www.painphysicianjournal.com

Background: Cervical interlaminar epidural injection (CIEI) is widely used in the management of acute or chronic neck and upper extremity pain. There is no consensus regarding the optimal volume of solution to be used for CIEI.

Study Design: Randomized, double blind controlled trial.

Objective: The purpose of this study was to evaluate how many spinal segments would be covered with different volumes of contrast medium, given by fluoroscopically guided CIEI, in efforts to establish the optimal volume of medication with consideration of clinical pathologic lesions.

Methods: One hundred and twenty-six CIEI were performed at C7-T1 in 133 patients. All patients were divided into 3 groups (A, B, and C) according to the amount of contrast medium used: 2.5 mL for group A, 5 mL for group B, and 10 mL for group C. The extent of contrast medium spread was determined by anteroposterior and lateral view under fluoroscopy.

Limitation: We did not evaluate the clinical outcomes with pain measurements during the study period.

Results: The total number of vertebral segments of contrast media spread and spreading range of caudad or cephalad were significantly different among the 3 groups ($P < 0.001$). However, groups B and C in cephalad spreading and groups A and B in caudad spreading did not show any significant difference. A proportion of the patients with a cephalad spread of up to C4 and C2 in group A (59.5% and 31%) was significantly different from that in the other 2 groups (92.9% and 69.1% in group B and 97.6% and 73.8% in group C) ($P < 0.001$).

Conclusion: Five mL for CIEI at C7-T1 could be an optimal volume for distribution to the lower cervical spine for degenerative cervical spinal diseases, as well as to the upper cervical spine for head and facial pain.

Key words: Cervical epidural block, epidural injection, cervical epidural interlaminar injection, distribution range, fluoroscopy, epidurogram, contrast medium, epidural spread

Pain Physician 2013; 16:155-164

Cervical interlaminar epidural injection (CIEI) is widely used in the management of a variety of acute, chronic, and cancer-related pain syndromes involving the face, head, shoulder, and upper extremities (1-11). The majority of pain from the neck and upper extremities is related to lesions below the C5 since degenerative cervical spine lesions occur most often at the C5-6 and C6-7, followed by C4-5 (12-14). Anatomically, there is a convergence of cranial and upper cervical primary afferents into a common synaptic region in the caudal medulla and the upper cervical cord, thus, the use of the CIEI for head and

face pain management could be rationalized (15-17).

In clinical practice, CIEIs have usually been performed at C6-7 or C7-T1 because the depth from the skin to the epidural space and the width of the epidural space are respectively the greatest at C7-T1, which is likely to be shallower with an upward direction (18,19). The effect of CIEI could be influenced by the anatomic spread of solution within the epidural space. Although the spread of the administered medication into the epidural space depends on several factors, such as volume of the drug, needle insertion site, speed of injection, epidural space contexture, patient position, age, height, and weight, the administered volume is a major factor in determining the spread range of injected solution to the targeted area (20).

Generally, 2 to 10 mL of solution for CIEI is thought to be adequate for pain management in adults (1,5-9,21,22). However, some authors advocate that volumes from 2 to 4 mL are sufficient to cover the entire cervical spine (5-9,21-24). As such, there is no consensus regarding the optimal volume of solution to be used for CIEI. The purpose of this study was to evaluate how many spinal segments would be covered by a different volume of contrast medium in fluoroscopically guided CIEI, in order to establish the optimal volume of solution with consideration of clinical pathologic lesions.

Methods

This study was conducted between March and July of 2010 at Ajou University Hospital. The study was approved by the Institutional Review Board of the hospital. Written informed consent was obtained from all patients before the study.

One hundred and thirty-three patients with a complaint of head, face, neck, and/or upper extremities pain undergoing a fluoroscopically guided CIEI were included. Exclusion criteria encompassed prior cervical surgery and contraindications for CIEI, such as coagulopathy and local infection. One hundred and twenty-six CIEIs were included in this study and 7 patients were dropped out. All patients were randomly divided into the 3 groups (A, B, and C) according to the amount of contrast medium used (2.5, 5, and 10 mL): Group A, 2.5 mL (1 mL of normal saline + 1.5 mL of iopamidol 370 mg I/mL [Iopamiro®,Braccos.p.a., Milan]); Group B, 5 mL (2 mL of normal saline + 3 mL of iopamidol 370 mg I/mL); and Group C, 10mL (4 mL of normal saline + 6 mL of iopamidol 370 mg I/mL). All CIEIs were performed using the paramedian approach to the C7-T1 level.

Patients were placed in the prone position on a table with arms at their sides. A pillow was placed under the chest and the neck was flexed with the head resting on a folded blanket. Anteroposterior (AP) view was obtained to ensure the C7-T1 interspace was located with a C-arm (OEC series 9800, General Electronics, USA). The injection site was prepared aseptically and a skin wheal was raised with 1 mL of 1% mepivacaine. After skin puncture, a 21 gauge (G) Tuohy needle was inserted at the paramedian site of the lower T1 and advanced to midline of C7-T1 interspinous space under the AP view and confirmed the needle to be placed parallel to the trajectory of the C7 and T1 spinous process under the lateral view. The needle was advanced to a few millimeters posterior to the line of the posterior articular pillar under the lateral view with exact midline of the C7-T1 interspinous space on the AP view. After that, the needle was meticulously advanced using loss of resistance (LOR) with a saline-filled syringe. When the needle reached the epidural space, a mixed solution of contrast medium and normal saline was injected at the rate of 0.3 – 0.4 mL/sec, using a 10 mL disposable syringe under real time fluoroscopic guidance. After 3 minutes of injecting the contrast medium, the extent of contrast medium spread was determined by AP and lateral radiographs of the cervical and thoracic spines, which was evaluated by one of the authors. Indication of spreading level was based on the upper and lower end of both lateral linings of contrast media in the AP view and posterior epidural lining in the lateral view.

The extent of contrast medium spread was determined by using the upper and lower endplates of the vertebra as a standard on the lateral view. The extent of contrast medium spread was determined depending on whether it included the intervertebral foramen or not, given the fact that the spinal root of each vertebral level is located in the intervertebral foramen. If the contrast medium reached the lower endplate of one vertebral body, it would be recorded as one level below when it was counted in the cephalad direction. If the contrast medium reached the upper endplate of one vertebral body, it would be recorded as that level, when it was counted in the cephalad direction. If the contrast medium reached the upper endplate of one vertebral body, it would be recorded as one level above when it was counted in the caudad direction. If the contrast medium reached the lower endplate of one vertebral body, it would be recorded as that level when it was counted in the caudad direction.

Statistical Analysis

According to our pilot study, this study required at least 33 patients per group to achieve a 2.5% level of significance and 90% power of test. The sample size was increased to 126 patients to account for any dropouts. Statistical analysis was performed using the statistical package (SPSS 12.0 for Windows, SPSS Inc, Chicago, IL, USA). Data were reported as the mean ± SD or number of patients. Patients' characteristics between the groups were compared using one way analysis of variance. The number of spinal segments and the number of patients were analyzed using a chi-square test. A P value < 0.05 was considered significant.

Results

Among the 133 patients selected in the study, 7 patients did not complete the study due to various reasons as follows: 2 in group A were vascular spreading, one in group B showed myelogram, and 4 in group C complained of pain during injection of contrast medium. Therefore, data from a total of 126 patients were included in the study. There were no serious complications related to the study procedures. There were no statistical differences in sex, age, height, weight, and disease classification for CIEI among the 3 groups (Table 1 and 2). Almost half of the study patients had cervical spinal disease, such as herniated nucleus pulposus and spinal stenosis (Table 2).

The total number of vertebral segments of cephalad and caudad spread of contrast media were 8.3 ± 3.1, 11.0 ± 3.7, and 13.6 ± 5.1, respectively, in groups A, B, and C. All patients in the study showed bilateral epidural distribution evenly. There were significant differences among these 3 groups (P < 0.01). The number of vertebral segments of cephalad spread of contrast media were 4.0 ± 2.1, 5.5 ± 1.3, 6.0 ± 1.3 in groups A, B, and C, respectively, and there were significant differences among the 3 groups (P < 0.001). However, there was no such difference between groups B and C. The number of vertebral segments of caudad spread of contrast media was 4.3 ± 2.3, 5.2 ± 3.6, 6.9 ± 4.3 in groups A, B, and C, respectively, and it showed signifi-

Table 1. *Demographic data and pain characteristics in the study population.*

	Group A (n = 42)	Group B (n = 42)	Group C (n = 42)
Age(yrs)	52.6 ± 15.1	51.5 ± 16.1	51.7 ± 13.1
Sex(M/F)	18/24	16/26	13/29
Height(cm)	160.4 ± 9.3	164.1 ± 7.1	160.4 ± 9.2
Weight(Kg)	60.0 ± 10.6	61.6 ± 10.0	60.4 ± 11.4
Duration of Symptoms (months)	8.2 ± 10.9	7.7 ± 12.8	8.9 ± 11.5
VAS	55.2 ± 26.4	64.9 ± 16.8	62.9 ± 21.5

Values are mean ± SD. No significant differences among the 3 groups. VAS: visual analogue scale (0: pain free, 100: maximal pain imaginary patient's feeling)

Table 2. *Disease classification in the study patients.*

Name of Diseases	Group A (n = 42) No. of patients(%)	Group B (n = 42) No. of patients(%)	Group C (n = 42) No. of patients(%)
Cervical HNP, stenosis	22 (52.3)	20 (47.2)	23 (54.8)
Other diseases	20 (47.2)	22 (52.4)	19 (45.2)
Myofascial pain syndrome	5	5	4
CRPS	3	3	4
Headache and facial pain	2	3	1
Frozen shoulder	1	5	2
Zoster associated pain	6	4	6
RA	1	0	2
Others	2	2	0
Total	42	42	42

HNP: herniated nucleus pulposus, CRPS: complex regional pain syndrome, RA: rheumatoid arthritis

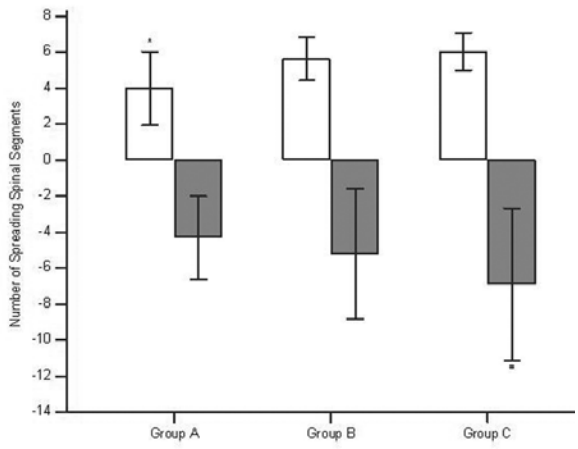

Fig. 1. *Number of spinal segments spreading contrast media after the injection of each volume of solution into the cervical epidural space. Negative means caudal spread. * Cephalad spreading spinal segments of contrast media shows a significant difference between group A and the other 2 groups ($P < 0.05$). # Caudal spreading spinal segments indicate a significant difference between the group C and the other 2 groups ($P < 0.05$). Data are presented as mean ± SD.*

cant differences among the 3 groups ($P < 0.001$). However, there was no difference between groups A and B (Fig. 1). The ranges of cephalad spreading segment with contrast media in patients with degenerative cervical spinal diseases were 3.9 ± 1.9, 5.4 ± 1.2, and 5.8 ± 1.2 in groups A, B, and C, respectively, and in patients with non-spinal diseases the ranges were 4.0 ± 2.1, 5.7 ± 1.1, and 6.2 ± 1.0 in groups A, B, and C, respectively. As a result, there was no significant difference between patients with degenerative cervical spinal diseases and non-spinal diseases in the 3 groups (Fig. 1).

The cephalad spread to the lower cervical spine under the C4 vertebra increased in proportion to the volume of contrast media, and it occurred in 59.5%, 92.9%, and 97.6% of the study patients in groups A, B, and C, respectively. There were significant differences between group A and the other 2 groups ($P < 0.001$). However, there was no difference between groups B and C. Generally, the upper cervical spine is related to headache and facial pain. The number of patients in which contrast media spread to the C2 vertebra were 31%, 69.1%, and 73.8% in groups A, B, and C, respectively, and there were differences in group A compared to groups B and C ($P < 0.001$); while there was no difference between groups B and C (Table 3).

Table 3. *Vertebral spreading segments of solution in the cervical interlaminar epidural injections on the radiographs.*

Spreading level of spine	Group A (n = 42)		Group B (n = 42)		Group C (n = 42)	
	Frequency (%)	Cumulative frequency (%)	Frequency (%)	Cumulative frequency (%)	Frequency (%)	Cumulative frequency (%)
Rostral spread						
C2	13 (31.0)	13 (31.0)*	29 (69.1)	29 (69.1)	31 (73.8)	31 (73.8)
C3	8 (19.0)	21 (50.0)	4 (9.5)	33 (78.6)	7 (16.7)	38 (90.5)
C4	4 (9.5)	25 (59.5)*	6 (14.3)	39 (92.9)	3 (7.1)	41 (97.6)
C5	2 (4.8)	27 (64.3)	3 (7.1)	42 (100)	1 (2.4)	42 (100)
C6	8 (19.0)	35 (83.3)	0 (0)	42 (100)	0 (0)	42 (100)
C7	7 (16.7)	42 (100)	0 (0)	42 (100)	0 (0)	42 (100)
Caudal spread						
T2	8 (19.1)	42 (100)	7 (16.7)	42 (100)	6 (14.3)	42 (100)
T3	10 (23.8)	34 (80.9)	7 (16.7)	35 (83.3)	7 (16.7)	36 (85.7)
T4	9 (21.4)	24 (57.1)	12 (28.5)	28 (66.6)	12 (28.5)	29 (69.0)
T5	10 (23.8)	15 (35.7)	3 (7.1)	16 (38.1)	3 (7.1)	17 (40.5)
T6-T9	3 (7.1)	5 (11.9) †	6 (14.3)	13 (31.0)	6 (14.3)	14 (33.4)
T10-T12	2 (4.8)	2 (4.8)	6 (14.3)	7 (16.7)	6 (14.3)	8 (19.1)
L1-L5	0 (0)	0 (0)	1 (2.4)	1 (2.4)	2 (4.8)	2 (4.8)

* There is a significant difference among the 3 groups ($P < 0.001$), however, no significant difference between groups 2 and 3. † There is a significant difference among the 3 groups ($P < 0.007$), however, no significant difference between groups 2 and 3.

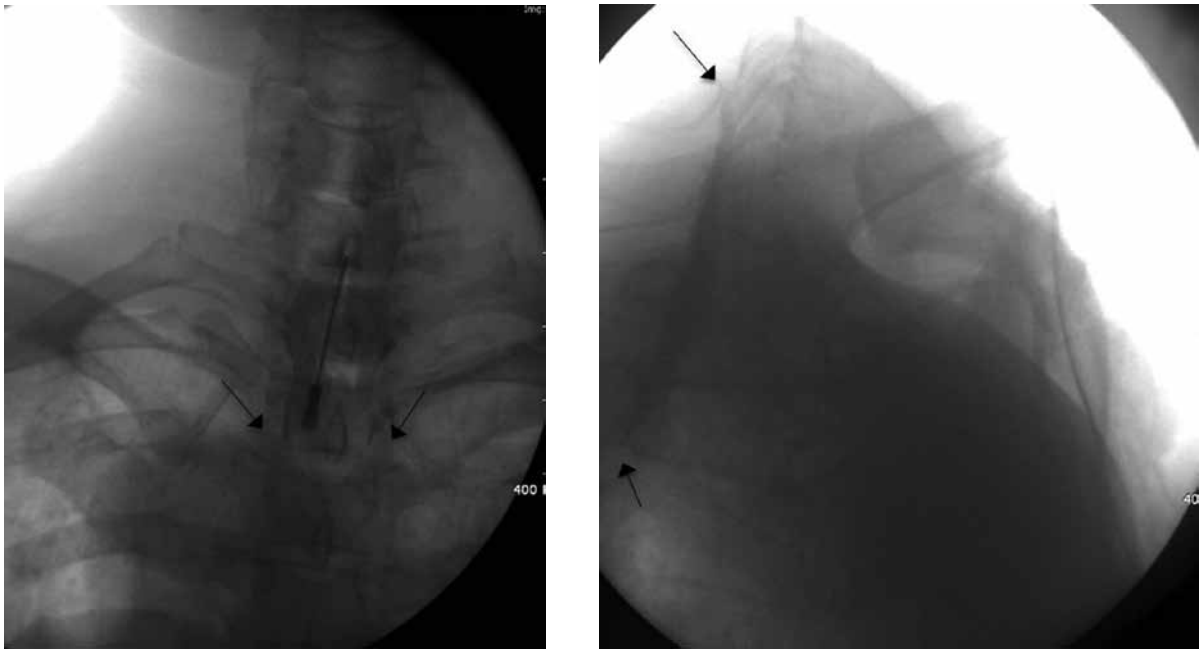

Fig. 2. *Epidurogram of 2.5 mL of contrast media injection for a 58-year-old male patient with right shoulder and neck pain due to cervical herniated nucleus pulposus. A. Lower portion of both lateral epidural lining with contrast media shows near the T2 lower endplate on the AP view. B. Contrast media were concentrated in the posterior part of the articular pillar and spread up to the upper border of the C6 articular pillar down to the lower endplate of T2 on the lateral view.*

The caudad spread to the T5 vertebra showed no difference between the 3 groups. The caudad spread below T6 was significantly less in group A compared to groups B and C ($P < 0.001$) (Table 3). There are examples of the distribution patterns of contrast media in the 3 groups (Figs. 2-4).

Discussion

CIEI needs to achieve a reliable spread of medication to the pathologic vertebral or nerve root level (23). Medications of CIEI spread both cranially and caudally from a site of injection (24). The distribution of medication of CIEI in the epidural space depends on the injection site, volume, the speed of injection, patient position, age, height, and weight (20). Volume is a major factor determining the spreading range of an injected solution. However, there are few previous reports on the optimal volume of solution for CIEI. In this study we evaluated how many spinal segments would be covered by different volumes of contrast medium in fluoroscopically guided CIEI, in order to establish the optimal volume of solution with consideration to clinical pathologic lesions. Our study showed that considering the minimum volume to get a target segment of vertebra, a 5 mL solution for CIEI at C7-T1 would be sufficient to treat degenerative cervical lesions and upper cervical lesions.

Generally, degenerative cervical diseases occur most commonly at the levels of C5-6 and C6-7, followed by C4-5. C6, C7, and C5 dorsal root ganglia are commonly inflammed or compressed (12-14). It should be necessary to distribute medications in the pathologic vertebral segment and the dorsal root ganglion. The successful entry into the cervical epidural space does not guarantee delivery of the medication to targeted areas (25). Contrast medium spread has a clear correlation with the extent of local anaesthetic block, and epidurography can help to predict the distribution of the drugs (26). It is important to determine the optimal volume of dose administered with consideration to the range and pattern of spread of the contrast medium (23,24,27).

Previous studies have shown that a smaller volume, such as 2 mL, can provide an appropriate dispersion of contrast in the cervical epidural space (23,24). In one study, the average level of cephalad spread with 2 mL of

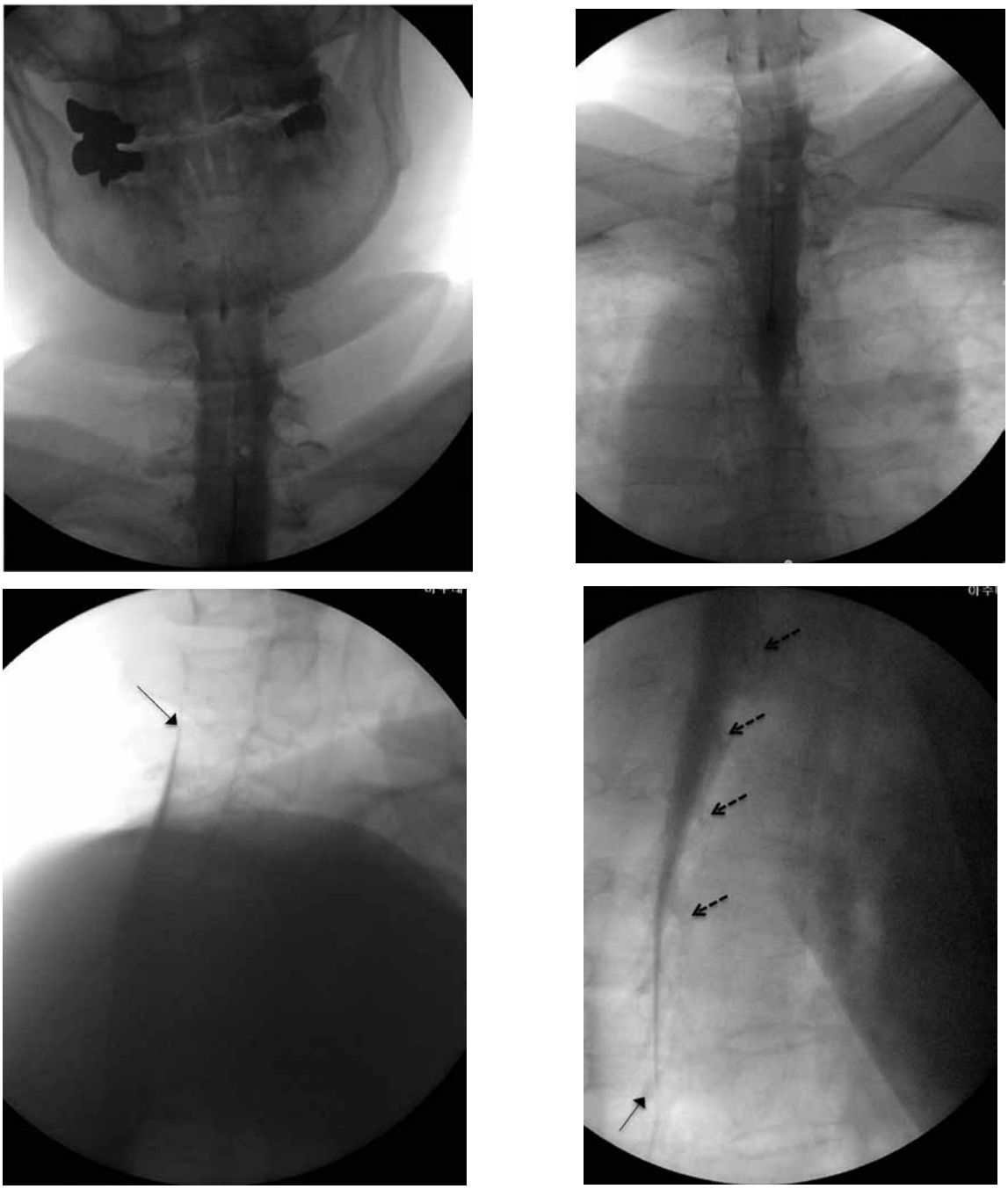

Fig. 3. *Epidurogram of 5 mL of contrast media injection for a 64-year-old female patient with right upper extremity pain due to cervical herniated nucleus pulposus. A. Both upper lateral epidural lining with contrast media shows at C3 on the AP view. B. Both lower lateral epidural lining with contrast media shows at T4 on the AP view. C. Contrast media were concentrated in the posterior part of the articular pillar and spread up to the upper border of the C3 articular pillar on the lateral view. D. Posterior epidural spreading of contrast media reaches to the pedicle of T5 and round shadows of T1-4 dorsal root ganglions (dotted arrow) on the lateral view.*

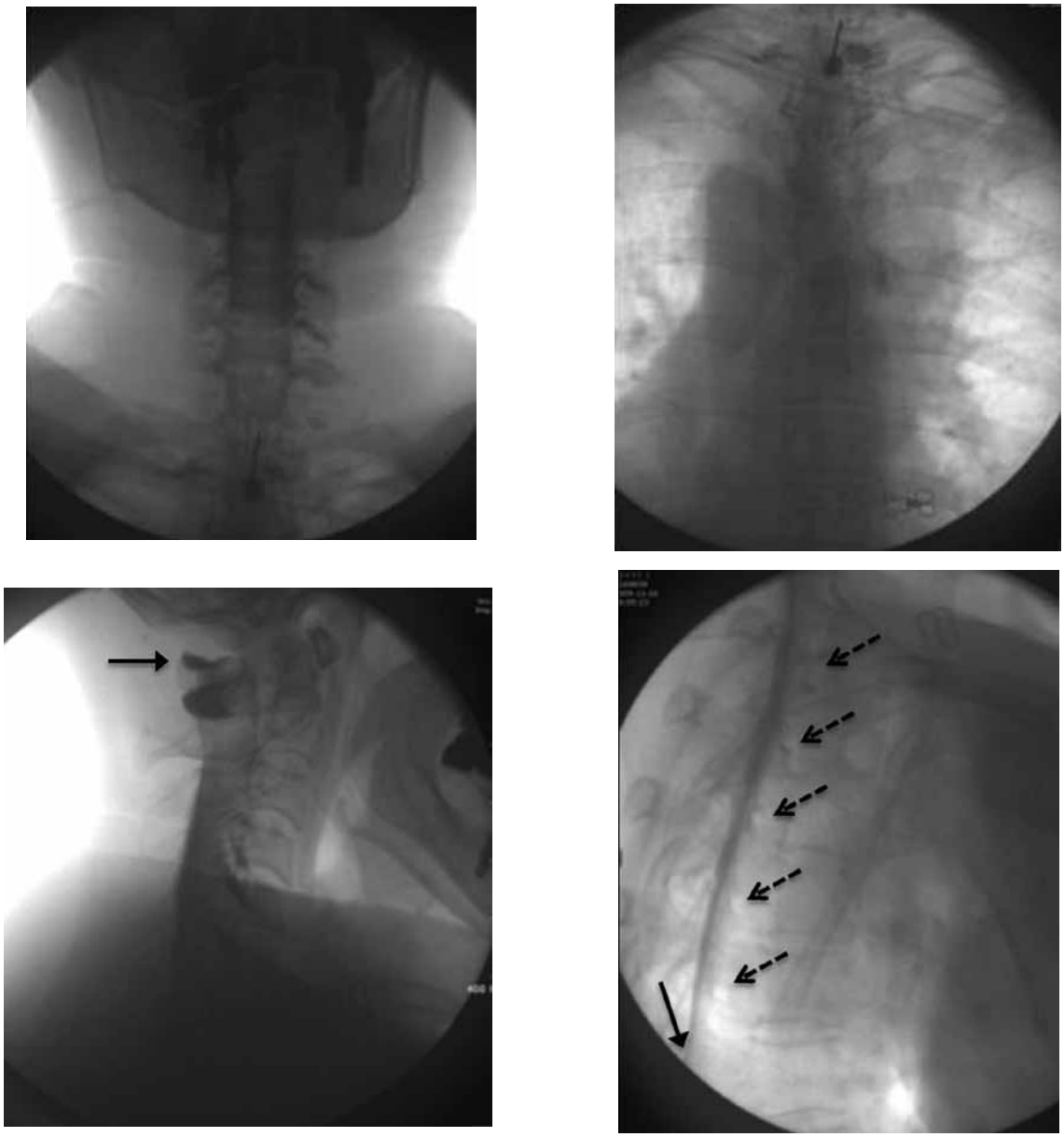

Fig. 4. *Epidurogram of 10 mL of contrast media injection for a 52-year-old male patient with left shoulder pain due to adhesive capsulitis. A. Both upper lateral epidural lining with contrast media shows at C2 on the AP view. B. Both lower lateral epidural lining with contrast media shows at T6 pedicle on the AP view. C. Contrast media spread evenly in the epidural space up to the atlas on the lateral view. D. Dense posterior epidural covering of contrast media reaches to T6 and round shadows of T1-5 dorsal root ganglions (dotted arrow) on the lateral view.*

contrast medium was 3.46 ± 1.04 (24). In another study, the average level of spread with 2 – 4 mL was 3.88 ± 1.01, and in all cases the cephalad spread was up to C3 (23). In that study, it was concluded that volumes of 2 to 4 mL for CIEI are sufficient to cover the lower cervical as well as the entire cervical epidural space. The reason why there are differences between the present study and the previous studies in the total volume of contrast medium to cover the cervical epidural space is not clear. However, in those studies (23,24), a test dose of contrast medium was

injected in order to confirm that the contrast was in epidural space, not intrathecal, before injection of the main dose, and the volume of the test dose was not specified clearly. In the present study, the volume of the test dose was included in the total dose. The present study showed that a 5 mL of solution in CIEI at C7-T1 would be needed for pain management of cervical degenerative diseases regardless of different pathologic segments. In contrast to previous studies (23,24,28), 2.5 mL was not enough to spread medication for pain management of cervical degenerative diseases, because in only about 60% of subjects did 2.5 mL cover the C4 vertebral segment in the present study.

Stojanovic et al (28) reported that 2 mL of contrast covered 3.14 vertebral segments and 51% of study subjects showed unilateral epidural distribution. In their study, they performed the CIEI with different needle entry sites between C4-5 and C7-T1 and did not evaluate the data according to different vertebral segments of needle entry site. In our study we performed CIEI at a constant needle entry site, C7-T1 at which the width of the epidural space is the largest (18,19), and in all patients covered the bilateral epidural space evenly with 5 mL of solution spread up to the C4 vertebral level in almost all study patients. There would be no need to take a risk of going for CIEI at the close vertebral segment of the disease because the cervical epidural space becomes narrower at higher vertebral segments.

Afferents from the trigeminal nerve and the first 3 cervical spinal nerves converge in the brainstem to form the cervicotrigeminal nucleus, creating the anatomical basis whereby pain from the cervical spine structures can be perceived in the head and/or face and vice versa (17,29). Therefore, any structure innervated by any of the first 3 spinal nerves may be the source of cervicogenic headache (30-32). Based on the above knowledge, there would need to be medication spread up to the C2 vertebral segment for management of headache and facial pain (16,33-35).

The C2 dorsal root ganglion is located inferior to the posterior arch of the atlas and superior to the lamina of the axis (36). For the management of headache and facial pain, medication in the CIEI should reach from the inferior to the posterior arch of the atlas to diffuse the medication into the upper 3 cervical segments. The contrast medium distributed up to the inferior border of the posterior arch of the atlas in the lateral view of fluoroscopy in about two-thirds of patients in groups B and C in this study, while contrast reached only one-third of group A patients there, implying that at least a 5 mL volume of solution is required to cover the upper 3 cervical nerves.

Complications

There were no serious complications, but 4 patients experienced temporary severe pain in the post neck and/or upper back, upper extremities, and upper chest during CIEI, while injecting over 5 mL of contrast media in group C. To the best of our knowledge, the reason for the pain induced by epidural injection would be that of the mechanical pressure effect from a large volume of medication on spinal nerve roots in the vertebral foramen during the spreading out of the epidural medication in the foramen (37). Since the capacity of the cervical peridural space to accommodate fluid is limited, Racz and Heavner insist that there are "warning signs" such as rapid onset of bilateral arm pain and chest pain or lower extremity pain when the epidural pressure reaches a level that causes ischemia of the spinal cord if the epidural fluid does not flow though the lateral transforaminal outlet producing an increase of pressure in the spinal cord, compromising the blood supply to the cord (38). They also recommend immediately flexing and rotating the patient's head to widen the intervertebral foramen if the patient complains of these warning signs (38,39).

When the volume is doubled from 5 mL to 10 mL, the average cervical spread can only be reliably increased by one vertebral level. Increasing the volume of injectate did not result in a linear increase in cervical epidural spread (13). Cervical spinal segments covered by one mL of the solution in groups A, B, and C are 1.6 ± 0.8, 1.1 ± 0.2, and 0.6 ± 0.1. A predictive number of cervical vertebral segments distributed by one mL of epidural medication is likely to decrease as the volume of injectate increases.

Limitations

One of the limitations of this study is that we did not evaluate the clinical outcome with a countable pain measurement during the study period. Future studies should be focused on clinical outcome according to different volumes in CIEI. The viscosity of this solution would be a little different from the practical solution, such as low concentration of local anesthetics and/or steroid. However, the spread pattern of contrast medium could be useful in predicting the degree of therapeutic solution spreading and outcome of CIEI as the medication covers pathologic spinal segments.

Conclusion

The volume of injectate in CIEI significantly influences the longitudinal spread in the cervical epidural space. A volume of 2.5 mL would not be enough to distribute to the lower cervical spine. The volume of 5 mL could provide sufficient dispersion in the lower cervical spine as well as the upper cervical spine. Over 5 mL of volume could produce sensory discomfort, such as injection pain in some patients. In conclusion, 5 mL of volume would be optimal to distribute the epidural medication in degenerative cervical diseases or headache and facial pain.

References

1. Huston CW. Cervical epidural steroid injections in the management of cervical radiculitis: Interlaminar versus transforaminal. A review. *Curr Rev Musculoskelet Med* 2009; 2:30-42.
2. He MW, Ni JX, Guo YN, Wang Q, Yang LQ, Liu JJ. Continuous epidural block of the cervical vertebrae for cervicogenic headache. *Chin Med J (Engl)* 2009; 122:427-430.
3. Stav A, Ovadia L, Sternberg A, Kaadan M, Weksler N. Cervical epidural steroid injection for cervicobrachialgia. *Acta Anaesthesiol Scand* 1993; 37:562-566.
4. Catchlove RF, Braha R. The use of cervical epidural nerve blocks in the management of chronic head and neck pain. *Can Anaesth Soc J* 1984; 31:188-191.
5. Diwan SA, Manchikanti L, Benyamin RM, Bryce DA, Geffert S, Hameed H, Sharma ML, Abdi S, Falco FJE. Effectiveness of cervical epidural injections in the management of chronic neck and upper extremity pain. *Pain Physician* 2012; 15:E405-E434.
6. Manchikanti L, Malla Y, Cash KA, McManus CD, Pampati V. Fluoroscopic epidural injections in cervical spinal stenosis: Preliminary results of a randomized, double-blind, active control trial. *Pain Physician* 2012; 15:E59-E70.
7. Manchikanti L, Cash KA, Pampati V, Malla Y. Fluoroscopic cervical epidural injections in chronic axial or disc-related neck pain without disc herniation, facet joint pain, or radiculitis. *J Pain Res* 2012; 5:227-236.
8. Manchikanti L, Malla Y, Cash KA, McManus CD, Pampati V. Fluoroscopic cervical interlaminar epidural injections in managing chronic pain of cervical post-surgery syndrome: Preliminary results of a randomized, double-blind active control trial. *Pain Physician* 2012; 15:13-26.
9. Manchikanti L, Cash KA, Pampati V, Wargo BW, Malla Y. Management of chronic pain of cervical disc herniation and radiculitis with fluoroscopic cervical interlaminar epidural injections. *Int J Med Sci* 2012; 9:424-434.
10. Manchikanti L, Malla Y, Wargo BW, Cash KA, McManus CD, Damron KS, Jackson SD, Pampati V, Fellows B. A prospective evaluation of bleeding risk of interventional techniques in chronic pain. *Pain Physician* 2011; 14:317-329.
11 Manchikanti L, Malla Y, Wargo BW, Cash KA, Pampati V, Fellows B. A prospective evaluation of complications of 10,000 fluoroscopically directed epidural injections. *Pain Physician* 2012; 15:131-140.
12. Rhee JM, Yoon T, Riew KD. Cervical radiculopathy. *J Am Acad Orthop Surg* 2007; 15:486-494.
13. Malcolm GP. Surgical disorders of the cervical spine: Presentation and management of common disorders. *J Neurol Neurosurg Psychiatry* 2002; 73:i34-41.
14. Jager HJ, Gordon-Harris L, Mehring UM, Goetz GF, Mathias KD. Degenerative change in the cervical spine and load-carrying on the head. *Skeletal Radiol* 1997; 26:475-481.
15. Poletti CE. Third cervical nerve root and ganglion compression: Clinical syndrome, surgical anatomy, and pathological findings. *Neurosurgery* 1996; 39:941-949.
16. Levin M. Nerve blocks in the treatment of headache. *Neurotherapeutics* 2010; 7:197-203.
17. Piovesan EJ, Kowacs PA, Oshinsky ML. Convergence of cervical and trigeminal sensory afferents. *Curr Pain Headache Rep* 2003; 7:377-383.
18. Han KR, Kim C, Park SK, Kim JS. Distance to the adult cervical epidural space. *Reg Anesth Pain Med* 2003; 28:95-97.
19. Aldrete JA, Mushin AU, Zapata JC, Ghaly R. Skin to cervical epidural space distances as read from magnetic resonance imaging films: Consideration of the "hump pad." *J Clin Anesth* 1998; 10:309-313.
20. Visser WA, Lee RA, Gielen MJ. Factors affecting the distribution of neural blockade by local anesthetics in epidural anesthesia and a comparison of lumbar versus thoracic epidural anesthesia. *Anesth Analg* 2008; 107:708-721.
21. Manchikanti L, Boswell MV, Singh V, Benyamin RM, Fellows B, Abdi S, Buenaventura RM, Conn A, Datta S, Derby R, Falco FJ, Erhart S, Diwan S, Hayek SM, Helm S, Parr AT, Schultz DM, Smith HS, Wolfer LR, Hirsch JA. Comprehensive evidence-based guidelines for interventional techniques in the management of chronic spinal pain. *Pain Physician* 2009; 12:699-802.
22. Michalek P, David I, Adamec M, Janousek L. Cervical epidural anesthesia for combined neck and upper extremity procedure: A pilot study. *Anesth Analg* 2004; 99:1833-1836.
23. Goel A, Pollan JJ. Contrast flow characteristics in the cervical epidural space: An analysis of cervical epidurograms. *Spine (Phila Pa 1976)* 2006; 31:1576-1579.
24. Kim KS, Shin SS, Kim TS, Jeong CY, Yoon MH, Choi JI. Fluoroscopically guided cervical interlaminar epidural injections using the midline approach: An analysis of epidurography contrast patterns. *Anesth Analg* 2009; 108:1658-1661.
25. Fredman B, Nun MB, Zohar E, Iraqi G, Shapiro M, Gepstein R, Jedeikin R. Epidural steroids for treating "failed back surgery syndrome": Is fluoroscopy really necessary? *Anesth Analg* 1999; 88:367-372.
26. Yokoyama M, Hanazaki M, Fujii H, Mizobuchi S, Nakatsuka H, Takahashi T, Matsumi M, Takeuchi M, Morita K. Correlation between the distribution of contrast medium and the extent of blockade during epidural anesthesia.

Anesthesiology 2004; 100:1504-1510.

27. Lee CJ, Jeon Y, Lim YJ, Bahk JH, Kim YC, Lee SC, Kim CS. The influence of neck flexion and extension on the distribution of contrast medium in the high thoracic epidural space. *Anesth Analg* 2007; 104:1583-1586.
28. Stojanovic MP, Vu TN, Caneris O, Slezak J, Cohen SP, Sang CN. The role of fluoroscopy in cervical epidural steroid injections: An analysis of contrast dispersal patterns. *Spine (Phila Pa 1976)* 2002; 27:509-514.
29. Bogduk N. The neck and headaches. *Neurol Clin* 2004; 22:151-171.
30. Becker WJ. Cervicogenic headache: Evidence that the neck is a pain generator. *Headache* 2010; 50:699-705.
31. Vanelderen P, Lataster A, Levy R, Mekhail N, van Kleef M, Van Zundert J. 8. Occipital neuralgia. *Pain Pract* 2010; 10:137-144.
32. Acar F, Miller J, Golshani KJ, Israel ZH, McCartney S, Burchiel KJ. Pain relief after cervical ganglionectomy (C2 and C3) for the treatment of medically intractable occipital neuralgia. *Stereotact Funct Neurosurg* 2008; 86:106-112.
33. Zhang J, Shi DS, Wang R. Pulsed radiofrequency of the second cervical ganglion (C2) for the treatment of cervicogenic headache. *J Headache Pain* 2011; 12:569-571.
34. Lee S, Sim S, Lee S, Chang I. Bipolar pulsed radiofrequency denervation of third occipital nerve in patient with cervicogenic headache. *Korean J Pain* 2008; 21:150-154.
35. Kim Y, Shin D, Hong K. C2 ganglion block for treatment of cervicogenic headache. *Korean J Pain* 1994; 7:273-276.
36. Paluzzi A, Belli A, Lafuente J, Wasserberg J. Role of the C2 articular branches in occipital headache: An anatomical study. *Clin Anat* 2006; 19:497-502.
37. Castagnera L, Maurette P, Pointillart V, Vital JM, Erny P, Senegas J. Long-term results of cervical epidural steroid injection with and without morphine in chronic cervical radicular pain. *Pain* 1994; 58:239-243.
38. Racz GB, Heavner JE. Cervical spinal canal loculation and secondary ischemic cord injury—PVCS—perivenous counter spread--danger sign! *Pain Pract* 2008; 8:399-403.
39. Kitagawa T, Fujiwara A, Kobayashi N, Saiki K, Tamai K, Saotome K. Morphologic changes in the cervical neural foramen due to flexion and extension: In vivo imaging study. *Spine (Phila Pa 1976)* 2004; 29:2821-2825.